Review

JOURNAL OF ENDOVASCULAR THERAPY
A SAGE Publication
An official publication of the ISEVS

Journal of Endovascular Therapy
2018, Vol. 25(3) 345–352

DOI: 10.1177/1526602818765248
www.jevt.org
SAGE

Below-the-Knee Retrograde Access for Peripheral Interventions: A Systematic Review

Rutger H. A. Welling, BSc[1], Olaf J. Bakker, MD, PhD[2], Dierk Scheinert, MD[3], Frans L. Moll, MD, PhD[1], Constantijn E. Hazenberg, MD, PhD[1], Jihad A. Mustapha, MD[4], Gert J. de Borst, MD, PhD[1], and Andrej Schmidt, MD[3]

Abstract

Purpose: To investigate the hypothesis that interventions involving retrograde below-the-knee (BTK) vessel punctures have an acceptably low complication rate and high procedural success. **Methods:** A systematic review was performed of the MEDLINE and Scopus databases for articles describing the results of BTK retrograde access for peripheral interventions. Outcome measures were access success, procedure success, and complications. A predefined subgroup analysis was performed of prospective studies to reduce the influence of possible reporting bias on outcomes. **Results:** Nineteen articles, including 3 prospective studies, were selected, including a total of 1905 interventions in 1395 patients (mean age 69.5 years; 918 men). The BTK vessels were punctured in 1168 (61.3%) of these interventions. Access was successful in 94.0% of BTK attempts, 86.0% of all lesions were successfully crossed using a retrograde access, and 84.0% of interventions achieved technical success. Forty-eight (4.1%) distal access site complications were reported. Vessel perforations were seen in 13 (1.1%) interventions, vasospasm in 5 (0.4%), and acute distal occlusions in 5 (0.4%). Predefined subgroup analysis of prospective studies showed similar results (p=0.24). **Conclusion:** A retrograde approach to facilitate peripheral endovascular interventions is a safe and successful technique and should be considered when an antegrade approach is not possible or fails to cross the lesion. Because of missing data on long-term outcomes and methodological shortcomings, real world data of retrograde access in nonexpert centers remains necessary before this technique can be advised to all interventionists dealing with peripheral artery disease.

Keywords

access site complications, below-the-knee access, endovascular interventions, peripheral artery disease, retrograde access, retrograde approach, tibial artery, vascular access

Introduction

Between 2000 and 2010, the global prevalence of peripheral artery disease (PAD) rose to 202 million individuals, primarily driven by the increase in the aged population.[1] A subset of PAD patients develop the ischemic rest pain, nonhealing wounds, or gangrene indicative of critical limb ischemia (CLI).[2] When treating severe PAD, the less invasive "endo-first" approach is advocated as studies have shown comparable results with bypass surgery.[3,4] However, when using the traditional antegrade approach for interventions in the infrainguinal arteries, 10% to 20% of endovascular interventions fail due to inability to cross a chronic total occlusion (CTO) or reenter the vessel lumen after subintimal crossing.[5,6]

In 1988, Tønnesen et al[7] were the first to demonstrate the possibility of navigating a peripheral CTO from a retrograde approach after failure via an antegrade access. Since then, many distal access sites have been used to percutaneously enter the vasculature from the retrograde direction, including

[1]Department of Vascular & Endovascular Surgery, University Medical Center Utrecht, the Netherlands
[2]Department of Vascular & Endovascular Surgery, Franciscus & Vlietland Hospital, Rotterdam, the Netherlands
[3]Department of Interventional Angiology, University Hospital Leipzig, Germany
[4]Department of Cardiovascular Medicine, Metro Health University of Michigan Health, Wyoming, MI, USA

Corresponding Author:
Rutger H. A. Welling, Department of Vascular Surgery, University Medical Center Utrecht, Heidelberglaan 100, Postbus 85500, Utrecht, 3584 CX, the Netherlands.
Email: r.h.a.welling@umcutrecht.nl

the anterior and posterior tibial[8] arteries, the peroneal artery,[9] the dorsalis pedis artery,[10] and various collateral and metatarsal[11] arteries.

Despite various step-by-step descriptions of the retrograde technique in the literature,[12–15] a below-the-knee (BTK) access might cause an unacceptably high rate of complications if not performed routinely in daily practice (in nonexpert centers), worsening the little patency that might be left in the small BTK vessels. This systematic review sought to investigate the hypothesis that interventions involving retrograde BTK vessel punctures have an acceptably low complication rate and high procedural success.

Methods

Literature Search and Article Selection

A search was conducted of the MEDLINE database and the Scopus citation index in accordance with current guidelines for reporting systematic reviews.[16] The search included terms for any type of retrograde access in peripheral interventions (see the Appendix) without addressing any exclusion criteria. The final database search was conducted October 31, 2017.

The title and abstract of all identified citations were reviewed by the first author (R.H.A.W.) to select full length articles involving endovascular interventions using any of the BTK arteries for retrograde access. Reviews, book chapters, letters to the editor, and articles not written in Dutch, German, or English were excluded, as were studies having ≤10 patients or patients treated before the year 2000. Likewise, articles that described punctures of both above- and below-the-knee arteries but did not associate the complications with the particular access site were also excluded. All articles of potential interest were discussed with the second author (O.J.B.). Finally, included articles underwent a reference cross-check to identify articles that were not found in the initial database search.

When different studies were suspected of having overlapping patient cohorts, for example, because of overlapping inclusion period and hospital, the study with the most included patients was chosen when agreed upon by the 2 reviewers. When deemed necessary, the authors were contacted to affirm or deny potential overlap in patient cohorts.

Bias Assessment

Quality of the included articles was assessed using the Methodological Index for Non-Randomized Studies (MINORS) checklist[17] because no randomized trials were expected. The MINORS checklist provides a score using 8 items for noncomparative studies and 12 items for comparative studies. A maximum of 2 points per item can be obtained for adequately addressing this item in the study. A high total score is associated with a low risk of reporting bias.

Data Extraction

Baseline variables were the type of study, the number of included patients, the number of treated limbs, the number of men, mean age, and baseline Rutherford category. Procedure-related variables included the access materials, periprocedural medication, the imaging modality employed during vessel access, whether an antegrade intervention was attempted before the retrograde access, access success, technical success (<30% residual stenosis), and access site–related complications (eg, dissections, acute occlusions, hematomas, arteriovenous fistulae, and pseudoaneurysms). When available, follow-up period, patency, target lesion revascularization (TLR), and limb salvage were also recorded.

Statistical Analysis

Continuous variables summarized as median and range were converted to a mean using published methods,[18] after which a grand mean was calculated. The PAD severity of the affected leg was dichotomized into claudication (Rutherford categories 0–3) and CLI (Rutherford categories 4–6). Other variables did not require remodeling of any sort. A predefined subgroup analysis was performed for the prospective studies to reduce the influence of possible reporting bias on outcomes. Independent *t* tests were computed using R (version 3.4.2; R Foundation for Statistical Computing, Vienna, Austria; *http://www.r-project.org*). The threshold of statistical significance was $p<0.05$.

Results

The search yielded 14,576 titles (4567 MEDLINE and 10,009 Scopus); removal of duplicates reduced the number to 10,395. Based on the title, 9912 articles were eliminated (Figure 1). Of the 483 articles left for abstract analysis, 3 studies[15,19,20] showed potential overlap; contact with the lead author confirmed no overlap in patients. The 53 remaining articles were cross-referenced, but no other relevant retrograde access studies were found. Finally, studies that did not include ≥10 punctures via the BTK arteries were excluded, leaving 19 articles for data abstraction.[5,12,14,15,19–33]

Characteristics of Included Studies

Among the 19 included articles, 3 studies[12,25,32] had a prospective design, the remaining 16 articles were retrospective analyses. The 2 comparative studies[20,26] scored 20

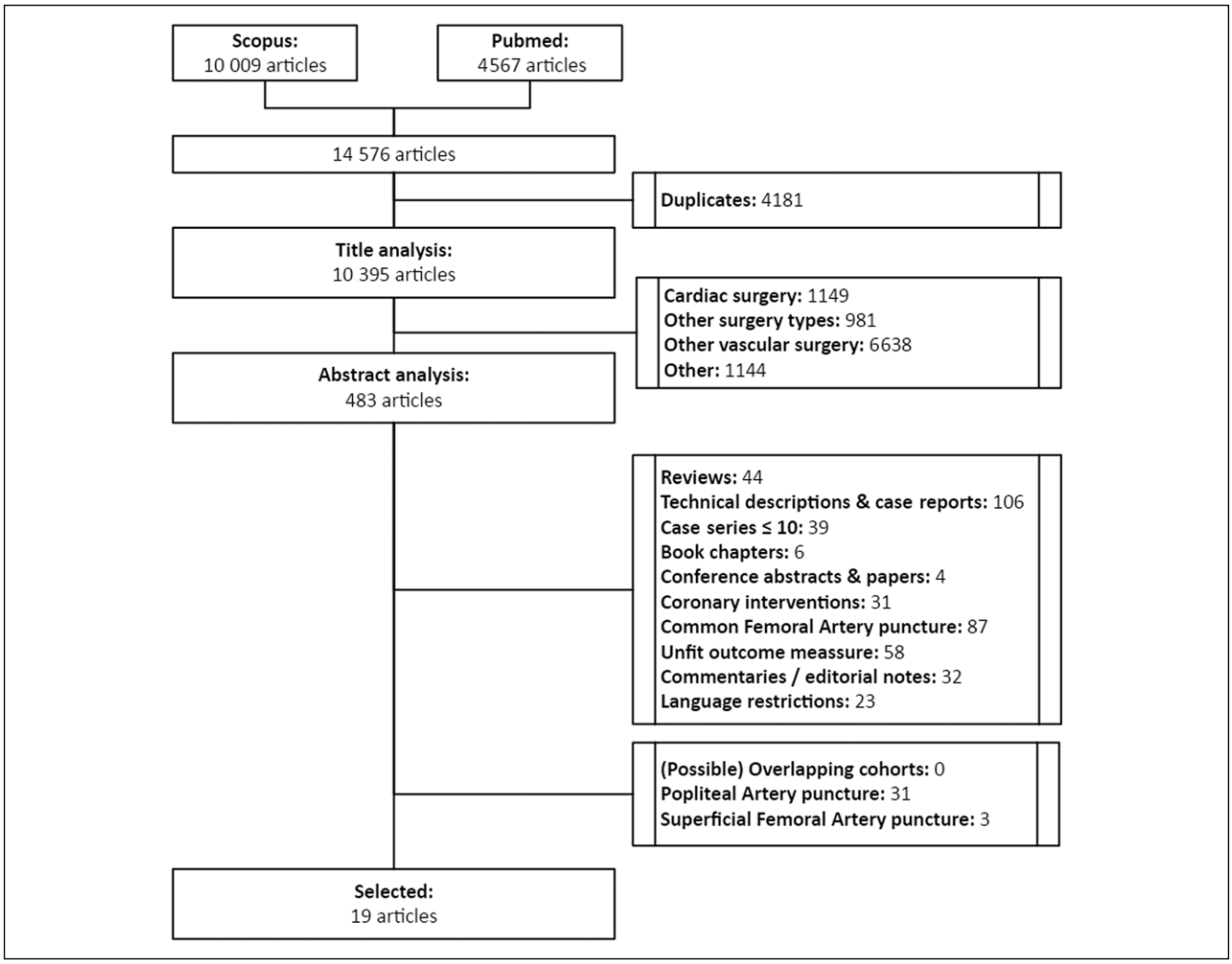

Figure 1. Flowchart of literature selection.

points on a 24-point scale for the MINORS assessment, while the 17 remaining studies averaged 10 points (range 3–14) on the 16-point scale for noncomparative studies.

A total of 1905 interventions were performed on 1395 patients (mean age 69.5 years; 918 men). Claudication was the indication for treatment in 334 (20.3%) limbs (49 Rutherford category 2 and 281 Rutherford category 3). CLI was found in 1312 (79.7%) patients (245 Rutherford category 4, 380 Rutherford category 5, and 58 Rutherford category 6). Patient characteristics were only partly described in 1 study[15] reporting 27 patients (representing 1.9% of the 1395 patients).

Intervention Strategy

BTK access accounted for 1168 (61.3%) of the 1905 interventions. The distribution of these puncture sites can be found in Table 1. The anterior tibial artery (ATA) or ATA/dorsalis pedis artery (DPA) combination were the most commonly used routes (500, 42.8%), followed by the posterior tibial artery (PTA) (457, 39.1%) and the peroneal artery (44, 3.5%). The needles most used were 21-G, either with or without an echogenic tip. One study employed a 20-G needle,[5] one a 22-G,[15] and another[20] did not describe the access set. Three studies defined the puncture height for the ATA/DPA as distal to the gastrocnemius head[20] or at the higher dorsum the foot, respectively.[5] The PTA was

Table 1. Distribution of 1168 Below-the-Knee Punctures.

Tibial	58 (5.0)
Anterior tibial	304 (26.0)
Anterior tibial / dorsalis pedis	196 (16.8)
Posterior tibial	457 (39.1)
Peroneal	44 (3.8)
Dorsalis pedis	107 (9.2)
Lateral plantar	1 (0.1)
Digital	1 (0.1)

punctured at or distal to the ankle.[5,23] Ultrasound was used to obtain access in 10 studies,[12,15,19,20,23,24,27,29,30,33] 6 allowed for a combination of ultrasound and fluoroscopy,[14,21,22,28,31,32] and 3 studies[5,25,26] described punctures using only fluoroscopy guidance.

Sheathless access was performed in 4 studies.[5,23,24,26] One study[14] described the use of a 2.9-F microsheath. A 4-F sheath was used in 7 studies,[12,19,22,27,29,30,33] of which 2 studies[27,33] allowed later use of a 6-F sheath to facilitate retrograde interventions. The most common guidewires were 0.014-inch and 0.018-inch; several studies allowed for an upsize to 0.035-inch wires,[23,29] dedicated CTO wires,[5,26,30] or crossing devices.[19,22]

The subintimal arterial flossing with antegrade-retrograde intervention (SAFARI) technique was employed in 193 patients, distributed over 4 studies.[19,21,25,31] In another 5 studies,[12,22,23,28,30] subintimal crossing was used to traverse the lesions of 102 patients (intentional or not). In 294 interventions, lesion crossing and balloon angioplasty ± stenting was performed solely using the retrograde access site.[14,15,20,5,27,32,33]

Final balloon angioplasty, either via the antegrade or retrograde route, was assisted by atherectomy in several patients, either using directional,[22,32] orbital,[27] rotational,[25,32] or laser[14,22] atherectomy. Drug-coated balloons were used in several patients in 2 studies.[12,32] Stents, when employed, were predominantly self-expanding. Puncture site hemostasis was achieved with either several minutes of manual compression, dedicated devices,[15,28,32,33] or balloon inflation.[12,23,32]

Medication

Only 3 articles[22,23,32] mentioned the use of sedation, with 1 patient treated under general anesthesia. Local anesthesia, most commonly using 1% lidocaine, was reported in 5 studies.[14,23,24,31,32]

In 2 articles, periprocedural medication use was not reported.[20,31] Two articles[14,32] mentioned medication using terms such as "full dose anticoagulant" or "vasodilators and anticoagulants were delivered intra-arterially." The remaining 15 articles reported intraoperative and postoperative medication to different extents. Heparin was reported with aimed activated clotting time of 200 to 300 seconds (n=1),[15] >250 seconds (n=4),[22,27–29] 250 to 300 seconds (n=3),[21,24,26] or >300 seconds (n=2).[12,33] Nitroglycerin was used in 12 articles[12,14,15,19,5,22–25,27,28,33] with dosages ranging from 100 to 400 µg; in two artiles[23,28] use was only in case of vasospasms or at operator discretion. Verapamil administration (2.5 mg) was reported in 5 articles.[15,24,25,27,33]

After the procedure aspirin was prescribed in 7 studies,[5,22,23,25,26,28,33] in 6 combined with clopidogrel.[5,22,25,26,28,33] A potassium antagonist (warfarin) was prescribed in 1 article after stent placement.[21]

Outcome

Access was successful in 1098 (94.0%) of 1168 BTK attempts. Unfortunately, the largest study[20] included in this review did not present crossing or interventional success. Excluding this study with 237 attempts and 213 successes, a lesion crossing rate of 90.5% (801/885) of successful accesses and 86.0% (801/931) of all attempts was reached. A reason for crossing failure was reported in only a minority of the failed crossings (22.6%); in 11 instances, the true lumen could not be found and in 8 the distal cap could not be punctured. After successful crossing of the lesion, technical success was achieved in 97.6% (782/801) of interventions. This can be regarded as 88.4% (782/885) of all successful BTK cannulations or 84.0% (782/931) of all attempted BTK accesses. Stents were reportedly placed in 141 patients in 9 studies.[15,21,5,22,23,25,28,29,32]

Among the 1168 BTK puncture attempts, 48 (4.1%) access-site complications (Table 2) were reported. The most common was vessel perforation (13, 1.1%), which was treated with external pressure,[15,25] prolonged balloon dilation,[23] or not treated at all.[29] Acute distal occlusion was observed in only 5 (0.4%) patients. One of these patients required a bypass,[5] and another was treated with additional balloon dilation.[25] Two cases of acute occlusion were related to a delay in heparin administration[23] and the use of a 6-F sheath[14]; no therapy was reported.

Spasms occurred in 5 (0.4%) patients despite the prophylactic use of antispasmodic medication in 4 of them.[12,25,27] In 1 patient, the interventionist converted to a femoral access,[27] and in a second the intervention was aborted and successfully repeated a week later.[12] In 3 other patients, spasms were treated with intra-arterial nitroglycerin.[25,30] In the studies where more than half of patients were treated using only a retrograde access,[15,5,27,33] no increase in access site complications was found compared to patients in whom the balloon catheter or stent was inserted antegradely (4.6% vs 5.9%, p=0.65). The remaining complications can be found in Table 2.

Follow-up was conducted in 14 of 19 studies reporting on 686 (55.2%) interventions.[11,14,20,22–32] Only 285 (22.9%) patients were followed for >6 months,[20,22–24,27–30] and just 125 (10.1%) patients had a follow-up of 12 months or more.[23,24,28,30] Commonly used follow-up variables, such as ulcer healing, primary vessel patency, or the need for TLR, were described in only 83 (6.7%) patients.[24,25,28]

Subgroup Analysis of Prospective Studies

In this subgroup, puncture of the tibial arteries was performed in 263 patients, using mainly the ATA and PTA. Access success was 93.2% (245/263). Reasons for 17 of the 18 failures were not reported; only the occurrence of vasospasm in the patient with the aborted procedure was noted.

Table 2. Access Site–Related Complications.[a]

	Retrospective Studies (n=902)	Prospective Studies Only (n=266)	All Studies (n=1168)	p
Dissection	—	1 (0.4)	1 (0.1)	0.42
Acute occlusion	4 (0.4)	1 (0.4)	5 (0.4)	0.71
Hematoma	4 (0.4)	2 (0.8)	6 (0.5)	0.68
Arteriovenous fistula	1 (0.1)	—	1 (0.1)	0.33
Vessel perforation	12 (1.3)	1 (0.4)	13 (1.1)	0.20
Pseudoaneurysm	5 (0.6)	—	5 (0.4)	0.26
Spasm	2 (0.2)	3 (1.1)	5 (0.4)	0.25
Bleeding	2 (0.2)	2 (0.8)	4 (0.3)	0.84
Ecchymosis	—	2 (0.8)	2 (0.2)	0.42
Local pain	—	4 (1.5)	4 (0.3)	0.42
Infections	—	2 (0.8)	2 (0.2)	0.42
Overall	30 (3.3)	18 (6.8)	48 (4.1)	0.24

[a]Data are presented as the counts (percentage).

After successful access, technical success was achieved in 211 (80.2%) patients. Inability to cross the lesion was the cause in 2 patients and failed lumen reentry in 5 patients; the reason for failure was not reported in 27 patients.

There were 18 (6.8%) complications (Table 2) related to retrograde access from the BTK arteries in the 3 prospective studies, including local pain (n=4), spasm (n=3), dissection (n=1), and an acute occlusion successfully treated by antegrade balloon dilation. As regards the incidence of complications, there was no significant differences between the prospective and retrospective studies (p=0.24).

Discussion

This systematic review of retrograde access using the BTK arteries documented a low complication rate (~4%) that was not affected by the use of the retrograde access site for the entire procedure. The technical success rates of the puncture and of the intervention were each >80%.

The crossing of a guidewire through a CTO from antegrade can be difficult because the hard fibrotic proximal cap can be impossible to penetrate or re-entry into the distal true lumen can be impossible after subintimal passage.[34] Animal studies have shown that over time collagen-rich fibrotic tissue replaces the proteoglycans and thrombus remnants. This change correlates with an increase in force required to puncture the cap,[35] whereas a distal cap is found to be thin or even nonexistent.[36] The recently reported results of the CTOP study (*c*hronic *t*otal *o*cclusion crossing approach based on *p*laque cap morphology)[37] found CTOs with a convex distal cap (as seen from a cranial-caudal view) were most likely to be crossed from a retrograde access. A more concave distal cap might simultaneously deflect the guidewire, leading to a perforation of the vessel, which is described as a complication in around 1% of interventions.

The strength of this systematic review lies in the broad search that led to the inclusion of 19 articles, including several prospective and multicenter studies, reporting 1168 BTK punctures. A previous study presented a review on femoral, popliteal, and pedal access, with technical descriptions and practical tips, but reported success rates in a smaller selection of articles.[38]

Limitations

A number of methodological limitations of our study should be mentioned. First, complications at the puncture site were seldom defined as research outcomes. Often, not more than a single line of text was used to describe any complications that occurred. In other cases, the presence or absence of complications was mentioned only in the discussion section. Furthermore, a retrospective study design is suboptimal for detecting nonmajor adverse events such as access site complications. A post-puncture stenosis or occlusion of the access site in most patients may not lead to direct clinical consequences and thus may go unnoticed. It is likely that minor access site complications are underreported. However, major complications, such as acute occlusions with direct clinical consequences that require additional invasive treatment, are nonetheless expected to be represented more clearly. The retrospective design of most studies also led to a limited duration of follow-up. Just under 1 in 4 patients was followed for a period of 6 months, and only 6.7% included important variables such as the need for TLR. Therefore, the midterm patency of the vessel cannot be presented with any certainty. Having said that, it is understandable that vessel patency is related to the actual diseased vessel and not to the vessel used for access.

As a second limitation, studies rarely reported a routine control duplex ultrasound or angiography of the puncture

site after intervention. Because of this limited use of imaging and the aforementioned lack of follow-up data, it is also not possible to assess the severity of distal vessel damage that could prevent future bypass surgery. Nevertheless, considering the large numbers of retrograde punctures and patients in this review, a high incidence of major complications would have been noticed. The same should hold true for the so-called "burned bridges" ramification that obviates future bypass surgery, although this is speculative.

A retrospective analysis may overestimate the puncture and technical success of a retrograde procedure. In the reported cases in which vascular access failed, the reason for failure or subsequent treatment was seldom described. Besides, no more than 2 articles[20,31] mentioned the number of attempts required for achieving access. It is also possible that patients with a failed retrograde puncture were not included in the retrospective study as this failed attempt was not registered in the study database. The amount of "operator discretion," including the use of imaging, sheathless approach, retrograde or antegrade intervention, combined with a low percentage of complications makes it impossible to attribute heightened risks to one of these variables. Furthermore, only 9 of 19 articles reported the number of stents placed, but another 3 articles[12,14,15] described the method of stent placement, without actual numbers given. This hampers the comparison of results between studies and increases the heterogeneity of overall results.

The lack of information on prior interventions also presents as a potential bias. Most studies were conducted at expert centers, so perhaps these patients had undergone unsuccessful antegrade interventions before. As earlier antegrade attempts were described inconsistently, a potential selection bias cannot be excluded. This potential risk of bias is unlikely to distort our primary outcome measure, the complications after BTK artery puncture, but may negatively influence the procedural success rates reported.

The subgroup analysis of prospective studies was an attempt to exclude a number of the above mentioned biases while maintaining a sufficient cohort for detecting complications. In the methodological reporting assessment, all 3 prospective studies were classified as "noncomparative." These articles had a mean MINORS score of 11 of 16 points, which is slightly higher (less risk of bias) compared to the noncomparative retrospective studies that scored a mean of 10 points. Nonetheless, none of the articles was clear of reporting bias.

A final limitation is that most studies were performed in expert centers, and most authors from expert centers underline the fact that a retrograde puncture has a certain learning curve. Thus, it might be debatable whether the same success and complication rates can be achieved in non-expert centers. Therefore, there is a need for large registry studies describing the results of retrograde access in a "real-world" setting. The largest, prospective, multicenter observational study[32] found in our search, although performed in expert centers, looked at tibial and pedal artery access in 197 patients. It showed high access and intervention success rates with few minor access site complications (5.6%) and no major complications related to access. As mentioned, future studies should include nonexpert centers and long-term standardized follow-up procedures, with ultrasound imaging of the access site and runoff vessels to detect possible postintervention occlusions.

In the studies included in this review, 1 in 5 patients were treated for claudication, with the majority (84%) classified as Rutherford stage 3. Current guidelines discourage endovascular treatment of claudicants merely to prevent the progression to CLI.[39] However, in lifestyle-limiting disease that is unresponsive to conservative therapy (ie, medication, supervised exercise), endovascular therapy should be an alternative in our opinion. When this intervention fails using the antegrade approach, a retrograde access should be considered, though with regard to the number of patent outflow vessels (reluctantly with single vessel runoff) and the interventionist's experience.

Conclusion

This systematic review showed that retrograde access in BTK vessels to facilitate peripheral interventions is a safe and successful technique and should be considered when a conventional antegrade intervention is not possible. However, major methodological shortcomings were present in all included studies, and data on midterm outcomes after retrograde access are lacking. Therefore, real world data of retrograde access in nonexpert centers are necessary before this technique can be advised to all interventionists dealing with PAD.

Appendix

Search 1 query: Scopus searched October 31, 2017, on title, abstract, or keywords: (retrograde OR tibi* OR pedal OR poplitea* OR peroneal OR below-the-knee OR btk) AND (access OR approach OR crossing OR puncture OR intervention OR recanalization OR revascularization OR angioplasty)) AND (artery OR arterial).
Search 2 query: PubMed searched October 31, 2017, on title and abstract: (retrograde OR tibi* OR pedal OR poplitea* OR peroneal OR below-the-knee OR btk) AND (access OR approach OR crossing OR puncture OR intervention OR recanalization OR revascularization OR angioplasty) AND (artery OR arterial).

Declaration of Conflicting Interests

The author(s) declared no potential conflicts of interest with respect to the research, authorship, and/or publication of this article.

Funding

The author(s) received no financial support for the research, authorship, and/or publication of this article.

References

1. Fowkes FG, Rudan D, Rudan I, et al. Comparison of global estimates of prevalence and risk factors for peripheral artery disease in 2000 and 2010: a systematic review and analysis. *Lancet*. 2013;382:1329–1340.
2. Writing Committee Members, Gerhard-Herman MD, Gornik HL, et al; ACC/AHA Task Force Members. 2016 AHA/ACC guideline on the management of patients with lower extremity peripheral artery disease: executive summary. *Vasc Med*. 2017;22:NP1–NP43.
3. Forbes JF, Adam DJ, Bell J, et al; BASIL trial participants. Bypass versus Angioplasty in Severe Ischaemia of the Leg (BASIL) trial: Health-related quality of life outcomes, resource utilization, and cost-effectiveness analysis. *J Vasc Surg*. 2010;51(5 Suppl):43S–51S.
4. Garg K, Kaszubski PA, Moridzadeh R, et al. Endovascular-first approach is not associated with worse amputation-free survival in appropriately selected patients with critical limb ischemia. *J Vasc Surg*. 2014;59:392–399.
5. Montero-Baker M, Schmidt A, Bräunlich S, et al. Retrograde approach for complex popliteal and tibioperoneal occlusions. *J Endovasc Ther*. 2008;15:594–604.
6. Met R, Van Lienden KP, Koelemay MJ, et al. Subintimal angioplasty for peripheral arterial occlusive disease: a systematic review. *Cardiovasc Intervent Radiol*. 2008;31:687–697.
7. Tønnesen KH, Sager P, Karle A, et al. Percutaneous transluminal angioplasty of the superficial femoral artery by retrograde catheterization via the popliteal artery. *Cardiovasc Intervent Radiol*. 1988;11:127–131.
8. Botti CF, Ansel GM, Silver MJ, et al. Percutaneous retrograde tibial access in limb salvage. *J Endovasc Ther*. 2003;10:614–618.
9. Zhuang KD, Tan SG, Tay KH. The "SAFARI" technique using retrograde access via peroneal artery access. *Cardiovasc Intervent Radiol*. 2012;35:927–931.
10. Hansen A, Krawzcynski H, Lacher F. Retrograde transpedal recanalisation of tibial artery occlusion. *Vasa*. 2009;38:249–253.
11. Manzi M, Palena LM. Retrograde percutaneous transmetatarsal artery access: new approach for extreme revascularization in challenging cases of critical limb ischemia. *Cardiovasc Intervent Radiol*. 2013;36:554–557.
12. Hanna EB, Prout DL. Combined radial-pedal access strategy and radial-pedal rendezvous in the revascularization of complex total occlusions of the superficial femoral artery (the "no femoral access" strategy). *J Endovasc Ther*. 2016;23:321–329.
13. Schmidt A, Bakker OJ, Bausback Y, et al. The tibiopedal retrograde vascular access for challenging popliteal and below-the-knee chronic total occlusions: literature review and description of the technique. *J Cardiovasc Surg (Torino)*. 2017;58:371–382.
14. Walker C. Pedal access in critical limb ischemia. *J Cardiovasc Surg (Torino)*. 2014;55:225–227.
15. Mustapha JA, Saab F, McGoff T, et al. Tibio-pedal arterial minimally invasive retrograde revascularization in patients with advanced peripheral vascular disease: the TAMI technique, original case series. *Catheter Cardiovasc Interv*. 2014;83:987–994.
16. Liberati A, Altman DG, Tetzlaff J, et al. The PRISMA statement for reporting systematic reviews and meta-analyses of studies that evaluate healthcare interventions: explanation and elaboration. *BMJ*. 2009;339:b2700.
17. Slim K, Nini E, Forestier D, et al. Methodological Index for Non-Randomized Studies (MINORS): development and validation of a new instrument. *ANZ J Surg*. 2003;73:712–716.
18. Hozo SP, Djulbegovic B, Hozo I. Estimating the mean and variance from the median, range, and the size of a sample. *BMC Med Res Methodol*. 2005;5:13.
19. Mustapha JA, Saab F, Diaz L, et al. Utility and feasibility of ultrasound-guided access in patients with critical limb ischemia. *Catheter Cardiovasc Interv*. 2013;81:1204–1211.
20. Mustapha JA, Diaz-Sandoval LJ, Jaff MR, et al. Ultrasound-guided arterial access: outcomes among patients with peripheral artery disease and critical limb ischemia undergoing peripheral interventions. *J Invasive Cardiol*. 2016;28:259–264.
21. Spinosa DJ, Harthun NL, Bissonette EA, et al. Subintimal arterial flossing with antegrade-retrograde intervention (SAFARI) for subintimal recanalization to treat chronic critical limb ischemia. *J Vasc Interv Radiol*. 2005;16:37–44.
22. Rogers RK, Dattilo PB, Garcia JA, et al. Retrograde approach to recanalization of complex tibial disease. *Catheter Cardiovasc Interv*. 2011;77:915–925.
23. Gür S, Oğuzkurt L, Gürel K, et al. US-guided retrograde tibial artery puncture for recanalization of complex infrainguinal arterial occlusions. *Diagn Interv Radiol*. 2013;19:134–140.
24. Bazan HA, Le L, Donovan M, et al. Retrograde pedal access for patients with critical limb ischemia. *J Vasc Surg*. 2014;60:375–381.
25. Ruzsa Z, Nemes B, Bánsághi Z, et al. Transpedal access after failed anterograde recanalization of complex below-the-knee and femoropopliteal occlusions in critical limb ischemia. *Catheter Cardiovasc Interv*. 2014;83:997–1007.
26. Venkatachalam S, Bunte M, Monteleone P, et al. Combined antegrade-retrograde intervention to improve chronic total occlusion recanalization in high-risk critical limb ischemia. *Ann Vasc Surg*. 2014;28:1439–1448.
27. Kwan TW, Shah S, Amoroso N, et al. Feasibility and safety of routine transpedal arterial access for treatment of peripheral artery disease. *J Invasive Cardiol*. 2015;27:327–330.
28. Sabri SS, Hendricks N, Stone J, et al. Retrograde pedal access technique for revascularization of infrainguinal arterial occlusive disease. *J Vasc Interv Radiol*. 2015;26:29–38.
29. El-Sayed H, Bennett ME, Loh TM, et al. Retrograde pedal access and endovascular revascularization: a safe and effective technique for high-risk patients with complex tibial vessel disease. *Ann Vasc Surg*. 2016;31:91–98.
30. Goltz JP, Planert M, Horn M, et al. Retrograde transpedal access for revascularization of below-the-knee arteries in patients with critical limb ischemia after an unsuccessful antegrade transfemoral approach. *Rofo*. 2016;188:940–948.
31. Tay JS, Ching SS, Tan YK, et al. Endovascular retrograde recanalization in Asian critical limb ischaemia patients. *ANZ J Surg*. 2017;87:E61–E64.

32. Walker CM, Mustapha J, Zeller T, et al. Tibiopedal access for crossing of infrainguinal artery occlusions: a prospective multicenter observational study. *J Endovasc Ther*. 2016;23:839–846.
33. Zachariah JJ, Ratcliffe JA, Ruisi M, et al. Transpedal approach for iliac artery stenting: a pilot study. *Cardiovasc Revasc Med*. 2016;17:556–559.
34. Montero-Baker M. The retrograde approach for BTK chronic total occlusions: tools and techniques for achieving access in even the most complex cases. *Endovascular Today*. 2014;55–64.
35. Thind A, Strauss B, Teitelbaum A, et al. A novel method for the measurement of proximal fibrous cap puncture force in chronic total occlusions: the effect of increasing age. *EuroIntervention*. 2011;6:997–1002.
36. Ozawa N. A new understanding of chronic total occlusion from a novel PCI technique that involves a retrograde approach to the right coronary artery via a septal branch and passing of the guidewire to a guiding catheter on the other side of the lesion. *Catheter Cardiovasc Interv*. 2006;68:907–913.
37. Saab F, Jaff JR, Diaz-Sandoval LJ, et al. Chronic total occlusion crossing approach based on plaque cap morphology: the CTOP classification. *J Endovasc Ther*. 2018;25:284–291.
38. Kamper L, Haage P. Percutaneous access for endovascular therapy of PAOD [in German]. *Radiologe*. 2016;56:223–232.
39. Gerhard-Herman MD, Gornik HL, Barrett C, et al. 2016 AHA/ACC Guideline on the management of patients with lower extremity peripheral artery disease: executive summary: a report of the American College of Cardiology/American Heart Association Task Force on Clinical Practice Guidelines. *J Am Coll Cardiol*. 2017;69:1465–1508.